


**PLASMAPHERESIS IN PATIENT WITH
GUILLAIN-BARRE SYNDROME OF THE INTENSIVE
CARE UNIT**

Vicky Muhammad Ramdhani, Suwarman, Reza Widiyanto

Sudjud and Erwin Pradian



PLASMAPHERESIS IN PATIENT WITH GUILLAIN-BARRE SYNDROME OF THE INTENSIVE CARE UNIT

^{1*} Vicky Muhammad Ramdhani

Fellowship Intensive Care: Faculty of Medicine Universitas Padjadjaran Dr. Hasan Sadikin
General Hospital

² Suwarman

Lecturer, Faculty of Medicine Universitas Padjadjaran Dr. Hasan Sadikin General Hospital

*Corresponding Author's E-mail: dr.suwarman@yahoo.co.id

³ Reza Widiyanto Sudjud

Lecturer, Faculty of Medicine Universitas Padjadjaran Dr. Hasan Sadikin General Hospital

*Corresponding Author's E-mail: reza.widiyanto.sudjud@unpad.ac.id

⁴ Erwin Pradian

Lecturer, Faculty of Medicine Universitas Padjadjaran Dr. Hasan Sadikin General Hospital

*Corresponding Author's E-mail: pradian1@yahoo.com

Abstract

Purpose: The purpose of writing this case report is to determine the importance of patient treatment using appropriate and specific therapies and the use of mechanical ventilation in the threat of respiratory failure of patients with GBS.

Methodology: We presented a case of 47 years old man with chief complaint of weakness in both upper and lower extremities. The patient was diagnosed with GBS and plasmapheresis was performed.

Findings: Holistic intensive care together with plasmapheresis has been shown to improve the survival of patients with GBS. In the current study, the patient was admitted for 1 day in HCU before he experienced difficulty in breathing, was intubated, and transferred to ICU. Plasmapheresis was performed six times in the ICU. The patient progressively improved until he was discharged to the HCU on 10th day of ICU admission.

Unique contribution to theory, practice, and policy: Holistic intensive care together with plasmapheresis has been shown to improve the survival of patients with GBS. From the current study, we recommend healthcare practitioners to perform either IVIG therapy or plasmapheresis for GBS patient

Keywords: *Guillain-Barre Syndrome, Intensive Care, Plasmapheresis*

INTRODUCTION

Guillain-barre syndrome (GBS) is a disorder that occurs when the immune system is used to attack the peripheral nervous system leading to muscle weakness and paralysis. GBS is usually triggered by an infectious or non-infectious process. Infections generally originate from the upper respiratory tract, gastroenteritis, vaccination or neoplastic diseases; whereas noninfection arise from surgery, pregnancy, epidural anesthesia, drugs. The hallmark of this disease is acute symmetric ascending flaccid paralysis with or without sensory changes in the body. In general, this disease rarely occurred, but might result in life threatening conditions when the autonomic nervous system and respiratory muscles were involved (Mishra, Tiwari & Gudi, 2017; Verboon, van Doorn & Jacobs, 2017).

The basic disease process of GBS is immunology. The antibodies directly attack the peripheral nerve tissue thereby damaging peripheral myelin, Schwann cells, axon cells (primary or secondary) and result in progressive muscular weakness and more severely respiratory system dysfunction that require mechanical ventilation support, thereby increasing mortality and morbidity (Bhagat, Dash, Chauha, Khanna & Bithal, 2014).

Guillain Barre Syndrome is divided into several subtypes, including acute inflammatory demyelinating polyradiculoneuropathy (AIDP), acute motor axonal neuropathy (AMAN), acute motor and sensory axonal neuropathy (AMSAN), and Miller Fisher syndrome. Its incidence is between 1-2 events per 100,000 people. The subtype of GBS incidence varies from country to country. In European and North American countries AIDP were more dominant in 90% of cases, about 5% of cases were axonal subtypes. The safest subtypes were found in China and Japan. In the United States, Central America, Japan and China, 37-47% axonal subtypes were obtained and Miller Fisher subtypes were around 5%. Whereas the incidence of AIDP and AMAN subtypes was almost the same in India (Verboon, van Doorn & Jacobs, 2017; McGrogan, Madle, Seaman & De Vries, 2009).

Standard criteria for the diagnosis of GBS were published by the National Institute of Neurological and Communicative Diseases (NINCDS) in 1978. These criteria included a clinical picture of a condition of progressive muscle weakness, relatively symmetrical with or without sensory involvement and hyporeflexion. Progressive motor weakness in more than one limb and areflexia were the two clinical features needed for the diagnosis of GBS. This condition is relatively symmetrical with mild sensory symptoms, cranial nerve involvement, autonomic dysfunction, albuminocytological dissociation and electrodiagnosis might help to establish the diagnosis. The main symptoms of SGB are oculomotor dysfunction, ataxia and areflexia (McGrogan, Madle, Seaman & De Vries, 2009).

Guillain Barre Syndrome has an acute onset with progression of more than 10-12 days before reaching plateau (without worsening or repairing) followed by a gradual healing process. Patients are usually in bed rest and mechanical ventilators for 2-3 days. Respiratory system dysfunction in GBS is caused by phrenic nerve disorders and loss of motor innervation to the intercostal muscles, abdomen and respiratory accessories (Bhagat, Dash, Chauha, Khanna & Bithal, 2014).

Patients with GBS had an increased risk for complications such as pneumonia (54%), sepsis (24%), cardiac arrhythmia (22%), ileus and/ or intestinal perforation, deep vein thrombosis (DVT), pulmonary thromboembolism, gastrointestinal bleeding and colitis pseudomembrane. Patients who used mechanical ventilation had a higher mortality rate (8.5%) than those who did not use mechanical ventilation (5–6.5%) based on a 1-year study (González, Guerra, Delgado, Uribe, ... & Hernández, 2016).

Treatment of GBS is Therapeutic Plasma Exchange (TPE) and Intravenous Immunoglobulin (IVIG). Both of these treatments have the same effectiveness. Previous study had shown that mechanical ventilation assistance is important in patients with severe conditions. Management in the Intensive Care Unit (ICU) in the form of physical therapy, chest physiotherapy, eye care, gastrointestinal and bladder care, position and bed that can prevent the formation of wounds, adequate nutrition and psychological support. However, the study did not emphasize the use of plasmapheresis as the specific management of GBS. (Bhagat, Dash, Chauha, Khanna & Bithal, 2014).

Plasmapheresis is removal and exchange of plasma in large volume that aimed to clear pathological substances such as pathological antibodies, immune complexes, and cytokines. Plasmapheresis is beneficial when applied within the first 4 weeks of onset but largest effect was seen when started early (within the first 2 weeks). Delayed initiation of plasmapheresis may lead to higher mortality and complication rates. (Kishore, Vijayabhaskar, Vardhan, Sainaresh, Sriramnaveen, Sridhar & Kumar, 2013).

We aim to investigate the importance of treating patients using appropriate and specific therapies and the use of mechanical ventilation in the threat of respiratory failure of patients with GBS in this study.

METHODOLOGY

We presented a case of 47 years old man diagnosed with GBS. The case report was conducted prospectively. Every data during the patient's ICU admission was recorded and presented in the case report.

FINDINGS

A-47-years old man was admitted with chief complaint of weakness in both upper and lower extremities. His muscle weakness progressed from lower to upper limbs starting four days prior admission. He was unable to stand nor walk, experienced difficulties in swallowing, dysarthria, and left sided facial drop. He had antecedent flu like symptoms and myalgia six days before general weakness appeared. Patient was treated in T Hospital Purwakarta and referred to Hasan Sadikin General Hospital after two days.

On physical examination, we found bilateral motor neuron paralysis and hypotonus with motor strength of 2/5 in all extremities. It was accompanied with decreased swallowing reflex, facial and accessory nerve paralysis. No fever was found, lung and cardiac function was in normal limit. Patient was diagnosed as Guillain Barre Syndrome and received mecobalamin, methylprednisolone (4x125 mg), Ceftriaxone and was planned for six times of plasmapheresis in the High Care Unit (HCU).

On the first day in the HCU, patient experienced difficulty in breathing and dyspnea, respiratory rate increased (30-32x/min). Patient was intubated and transferred to the ICU.

In the ICU, hemodynamic conditions, urine production, fluid balance was monitored, mechanical ventilation and double lumen catheter (CDL) was installed for plasmapheresis. On the first day of care, patient had stable condition with sedation, Ramsay score 3. SBP ranged from 125-140 mmHg, DBP ranged from 70-80 mmHg, heart rate 84-90x/min without support, respiratory rate 18-22x/min and SpO₂ 98-99% with ventilator mode SIMV PS 10 PEEP 6 FiO₂ 80% and tidal volume 320-360 ml. Temperature was seen 36.0-36.5 °C, urine production 0.4-0.5 ml/kgBW/hour, cumulative 40 ml/12 hours with balance +275 ml. Nasogastric tube had black production, bowel sound (+) without distension. He was diagnosed with respiratory failure due to GBS and suspected Hospital Acquired Pneumonia (HAP). Laboratory result shown hemoglobin 16.1 g/dl, hematocrite 48,3%, leukocyte 21.740/mm³, trombocytet 328.000/mm³, ureum 36 mg/dl, creatinine 1.17 mg/dl, protrombin time 9,7, INR 0,84, APTT 17,4, random blood glucose 146 g/dl, Na 135 mEq/l, K 4,1 mEq/l, Cl 103 mEq/l, Ca 4,93 mEq/l, Mg 1.7 mEq/l, albumin 2,9. BGA of pH 7,4, pCO₂ 33 mmHg, pO₂ 93,1 mmHg, HCO₃ 22,4 mmol/L, BE -0,3 mmol/L, SaO₂ 95,8 was found. Patient received antibiotics ceftazidime 3x2 gr iv and levofloxacin 1x750 mg iv, mecobalamine 1x500 mg iv, omeprazole 2x40 mg iv, midazolam 5 mg/hour, n-acetyl cysteine 3x200 mg po, nebulization with combivent every 8 hours during his treatment. Chest x-ray revealed cardiomegaly with lung edema dd/ bilateral pneumonia, no pneumothorax, tip of Endotracheal Tube (ETT) found at corpus vertebrae thoracic 1. He was then planned for plasmapheresis.

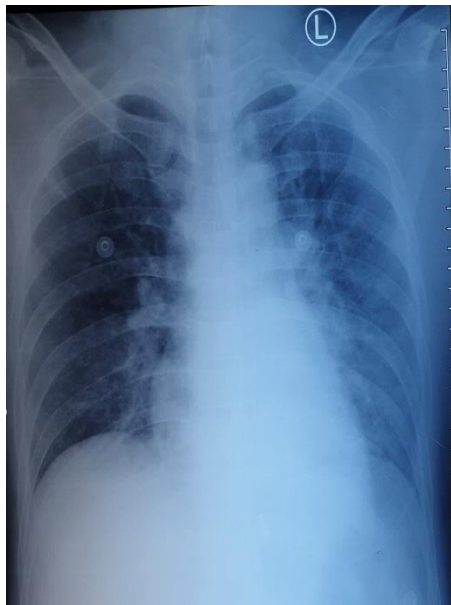


Figure 1: Chest x-ray on the first day of care in the ICU

Source: private documentation

On the second day of treatment, patient had stable condition, sedated with Ramsay score 2. SBP ranged from 115-125 mmHg, DBP 65-75 mmHg, heart rate 80-86 x/min, respiratory rate 16-18 x/min and SpO₂ 98-99% with ventilator mode r PS 10-12 PEEP 8 FiO₂ 50%. NGT had clear production, he was given liquid diet 500kcal. Blood gas analysis showed pH 7,35, pCO₂ 32,4 mmHg, pO₂ 129,1 mmHg, HCO₃ 20 mmol/L, BE -3,5 mmol/L, SaO₂ 98,26, PF ratio 214,8. First plasmapheresis was done with extracted volume 1553 ml and replacement volume 3409 ml.

On the third day of treatment, patient had stable condition, sedated with Ramsay score 2. SBP ranged from 125-135 mmHg, DBP 75-90 mmHg, heart rate 82-86 x/min, respiratory rate 16-18 x/min and SpO₂ 98-99% with ventilator mode PS 10 PEEP 8 FiO₂ 50%. NGT had clear production, he was given liquid diet 1000kcal. Blood gas analysis showed pH 7,46, pCO₂ 27,5 mmHg, pO₂ 110 mmHg, HCO₃ 21,3 mmol/L, BE -0,4 mmol/L, SaO₂ 97,1, PF ratio 317. Second plasmapheresis was done with extracted volume 2196 ml, replacement volume 4798 ml.

Patient experienced a 39°C fever on the fourth day intensive care. An additional paracetamol 4x1 gram iv was given. SBP ranged from 130-140 mmHg, DBP 80-90 mmHg, heart rate 90-96 x/menit, respiratory rate 18-20x/min and SpO₂ 98-99% with ventilator mode PS 10 PEEP 6 FiO₂ 50%. Laboratory results revealed hemoglobin 13.6

g/dl, hematocrite 39,4%, leukocyte $17.690/\text{mm}^3$, thrombocyte $273.000/\text{mm}^3$, ureum 42 mg/dl, creatinine 1.05 mg/dl, random blood glucose 120 g/dl, Na 138 mEq/l, K 3,5 mEq/l, Cl 104 mEq/l, Ca 4,8 mEq/l, Mg 2.2 mEq/l, albumin 3,1. Blood gas analysis showed pH 7,43, pCO_2 33,1 mmHg, pO_2 95,8 mmHg, HCO_3 22,4 mmol/L, BE -0,5 mmol/L, SaO_2 97,3, PF ratio 305. Another x-ray was done and showed an increase in bronchovascular distribution with bilateral perihiler and left pericardial infiltrates, bronchopneumonia was noted. Third plasmapheresis was done with extracted volume 2196 ml and replacement volume 4798 ml.

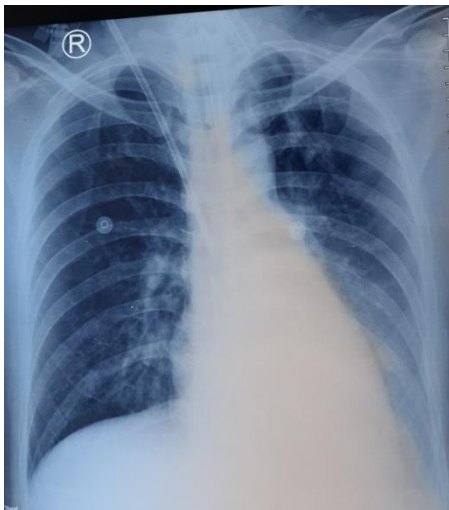


Figure 2: Chest X-ray on the fourth day in ICU

Source: private documentation

On the fifth day in the ICU, patient regained consciousness with Glasgow coma score $\text{E}_4\text{M}_3\text{V}_T$, without sedation. SBP ranged from 135-140 mmHg, DBP 85-90 mmHg, heart rate 80-84 x/minute, respiratory rate 18-20x/min and SpO_2 98-99% with ventilator mode PS 8 PEEP 5 FiO_2 50%. Liquid diet was increased to 1500 kkal. Blood gas analysis showed pH 7,40, pCO_2 36,6 mmHg, pO_2 133,6 mmHg, HCO_3 23,8 mmol/L, BE -0,5 mmol/L, SaO_2 98,5, PF ratio 296. Fourth plasmapheresis with extracted volume 2243 ml and replacement volume 5227 ml was done.

On day six, consciousness and motoric strength was seen to be improving in this patient with Glasgow coma score $\text{E}_4\text{M}_5\text{V}_T$, without sedation. SBP ranged from 110-120 mmHg, DBP 60-65 mmHg, heart rate 78-82 x/minute, respiratory rate 16-18x/min and SpO_2 98-99% with ventilator mode PS 5 PEEP 5 FiO_2 45%. Liquid diet remained 1500 kkal.

Blood gas analysis showed ,40, pCO₂ 35,2 mmHg, pO₂ 95,2 mmHg, HCO₃ 22,1 mmol/L, BE -1,5 mmol/L, SaO₂ 97,2, PF ratio 263.

On the seventh day in the ICU, patient was stable with Glasgow coma score E₄M₆V_T, without sedation. SBP ranged from 120-130 mmHg, DBP 70-80 mmHg, heart rate 80-86 x/menit, respiratory rate 18-20x/min and SpO₂ 98-99% with ventilator mode PS 5 PEEP 5 FiO₂ 45%. Blood gas analysis showed pH 7,41, pCO₂ 35,9 mmHg, pO₂ 92,3 mmHg, HCO₃ 23,4 mmol/L, BE -0,1 mmol/L, SaO₂ 99, PF ratio 231. Fifth plasmapheresis with extracted volume 2223 ml and replacement volume 5039 ml was done.

On the eighth day in the ICU, patient was stable with Glasgow coma score E₄M₆V_T, without sedation. SBP ranges from 125-135 mmHg, DBP 75-85 mmHg, heart rate 82-88 x/menit, respiratory rate 18-20x/min and SpO₂ 98-99% with ventilator mode PS 5 PEEP 5 FiO₂ 45%. Laboratory result revealed hemoglobin 14.3 g/dl, hematokrit 42,1%, leukosit 11.280/mm³, trombosit 327.000/mm³, ureum 30 mg/dl, kreatinin 1.02 mg/dl, gula darah sewaktu 129 g/dl, Na 136 mEq/l, K 3,9 mEq/l, Cl 103 mEq/l, Ca 4,5 mEq/l, Mg 2.6 mEq/l, albumin 3,3. Blood gas analysis showed pH 7,39, pCO₂ 37,3 mmHg, pO₂ 119 mmHg, HCO₃ 23,2 mmol/L, BE -0,9 mmol/L, SaO₂ 98,4, PF ratio 224. Culture results of pseudomonas aeroginosa was seen and is sensitive to gentamicin, amikacin, ciprofloxacin, meropenem but resistant to ceftazidime, cefazolin, tigecycline. On the chest x-ray on the eighth day (Figure 3) noted bronchopneumonia with improvement. Last plasmapheresis with extracted volume 2211 ml and replacement volume 4852 ml was done.

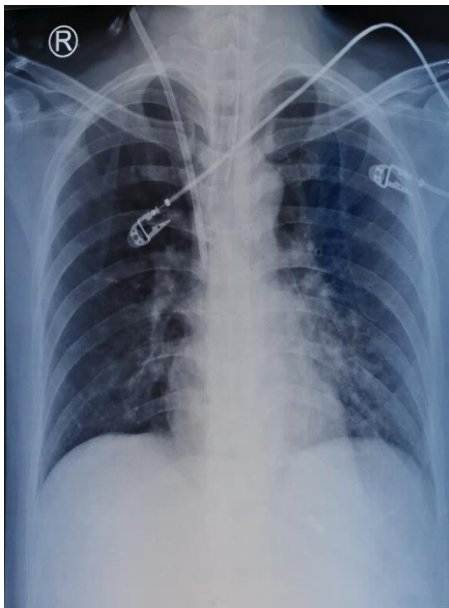


Figure 3: Chest X-ray on the 8th day in ICU

Source: private documentation

On day 9 in the ICU, patient was stable with Glasgow coma score E₄M₆V_T, without sedation. SBP ranges from 125-135 mmHg, DBP 70-80 mmHg, heart rate 80-84 x/minute, respiratory rate 16-18 x/min and SpO₂ 98-99% with ventilator mode PS 0 PEEP 5 FiO₂ 45%. Ventilator was then connected to T-piece and patient was extubated. He was observed one day in the ICU, afterwards, on the tenth day, transferred to the HCU.

DISCUSSION

Guillain Barre Syndrome is an acute condition of monophasic demyelinating neuropathy with the characteristics of progressive motor weakness of the limbs accompanied by areflexia. This condition initially was preceded by an infection which was generally viral in the majority of cases. Patients with GBS generally had a history of upper respiratory tract infection (40%) or gastroenteritis (20%) several weeks before the onset of the disease (Joshi, Patel, Gupta & Bajaj, 2016).

Patients in this case were admitted to the hospital with weakness on both limbs with lower part initially affected followed by upper limbs. He was unable to stand nor walk, had facial nervus paralysis, dysarthria and difficulty swallowing. A history of upper respiratory tract infection was admitted. Physical examination revealed the presence of hypotonus, decreased swallowing reflex, paralysis of the cranial nerves (facial and accessory) and motor strength deficit. Based on history and physical examination a diagnosis of Guillain Barre Syndrome was made. On second day of hospitalization, the patient had shortness of breath, intubation and mechanical ventilation assistance were performed. Muscle weakness in GBS leads to two types of respiratory failure, a medical emergency that requires immediate management (Dharmayanti & Astrawinata, 2017).

The diagnostic criteria commonly used for GBS are the criteria of NINCDS, which are the presence of a progressive weakness and hyporeflexion. These two symptoms are reliable to confirm a diagnosis of GBS and was experienced by this patient who was accompanied by a history of previous infection. Upper respiratory tract infection usually precedes the onset of GBS. Infection might originate from *Campylobacter jejuni*, cytomegalovirus (CMV), *Mycoplasma pneumonia*, Epstein – Barr virus and influenza virus. Surgery, immunization and pregnancy are also associated with GBS (Bhagat, Dash, Chauha, Khanna & Bithal, 2014).

The clinical manifestations of GBS are various, including the sensory symptoms, involvement of the cranial nerves (mostly facial nerve palsy), autonomic dysfunction that

influences heart rate and blood pressure, and the occurrence of respiratory failure which is the main cause of increasing number of morbidity and mortality. The main symptoms of SGB are weakness, paresthesias and loss of tendon reflexes. These neurological symptoms vary from patient to patient. Limb weakness (98%) was the most common manifestation, followed by dyspnea (47%) and sensory involvement (39%) which were common in demyelinating conditions (Bhagat, Dash, Chauha, Khanna & Bithal, 2014; Meena, Khadilkar & Murthy, 2011).

Laboratory examination such as cerebrospinal fluid (CSF) analysis and electrophysiology might support the diagnosis of GBS. Albumin cytological changes in CSF accompanied by an increase in the amount of protein and the number of mononuclear leukocytes ($10 / \text{mm}^3$) within normal limits are conditions that may indicate GBS. Increased protein concentrations in CSF (with normal cell counts) were only found in 50% of cases in the initial analysis, while at the peak of the disease more than 90% were found (Meena, Khadilkar & Murthy, 2011).

Facial and pharyngeal nerve palsy were usually seen in GBS. Weakness in diaphragm was due to involvement of phrenic nerve. Fifty percent cases had pain and about a third of patients treated require mechanical ventilation due to weakness in respiratory and oropharyngeal muscles. Tachycardia is commonly found, but may lead to severe autonomic nervous system dysfunction, including life-threatening arrhythmias, hypotension, hypertension, and gastrointestinal dysmotility. The incidence is 27–55% and is more common in the demyelinated than axonal form (Meena, Khadilkar & Murthy, 2011).

Pharmacological treatment in GBS patients is based on immunomodulation which consists of two options, first is plasmapheresis which aims to remove circulating antibodies and complement; and immunoglobulins that block the activation of T and B sets, neutralization of idiotypic antibodies, modulation of the release of Fc receptors on macrophages, suppression of various inflammatory mediators such as cytokines, chemokines and matrix metalloproteinases and inhibit complement activation. Both types of immunotherapy have the same effectiveness in terms of effects and costs. Treatment options are based on drug availability, drug safety profile and experience of the medical team. Corticosteroids are widely used to treat various autoimmune diseases, but in GBS corticosteroids do not have a significant effect on patient outcome (Bhagat, Dash, Chauha, Khanna & Bithal, 2014; González, Guerra, Delgado, Uribe, & Hernández, 2016).

Specific therapy for Guillain Barre Syndrome is recommended to start immediately after diagnosis is made. Specific therapy includes: (Van Doorn, Ruts, & Jacobs, 2008).

a. *Intravenous Immunoglobulin (IVIG)*

- Dose: 400 mg/kgBW day for 5 days.
- Time of administration: in two to four weeks after onset.
- Advantages: easy to administer, minimal side effect compared to TPE and more comfortable
- Side effects: fever, myalgia, headache, nausea, vomiting.
- Contraindication: patients with history of IVIG anaphylaxis

b. *Plasmapheresis*

- Dose:
 - i. The usual regimen is 5-6 times for two weeks, with total of plasma volume exchange 50 ml/kgBW, although there are different opinions regarding the correct frequency of plasmapheresis.
 - ii. Most studies stated that the benefit of plasmapheresis is seen in 4-6 times.
 - iii. The volume therapy administered is 1 – 1.5 times the total plasma volume with an estimated plasma volume (in liters) = $0.07 \times \text{body weight (kg)} \times (1 - \text{hematocrite})$
- Time of administration: plasmapheresis is very useful if given within the first 4 weeks after onset, but the effect is greatest if it is started earlier (within the first 2 weeks).
- Side effects: infection and sepsis

The principle of plasmapheresis is removal and exchange of plasma in large volume that aimed to clear pathological substances such as pathological antibodies, immune complexes, and cytokines. It is thought that the removal of this component is the main mechanism of action for plasmapheresis. However, this mechanism does not explain the length of the therapeutic response in some diseases. Additional evidence suggests that plasmapheresis may have an immunomodulatory effect in addition to the removal effect of immunoglobulin. Based on the guidelines by the American Academy of Neurology and the American Society for Apheresis (ASFA), plasmapheresis has been shown to be effective as a specific therapy for GBS. In this case, plasmapheresis was performed six times on treatment days 2,3,4,5,7 and 8. The first plasmapheresis with a target volume exchange of 2000 ml. Second plasmapheresis and the subsequent with a target volume exchange of 2500 ml. Albumin 5% and colloid was used during plasmapheresis. During ICU treatment, the patient responded well to plasmapheresis. Motor strength gained and

can be weaned from mechanical ventilation. The patient then was transferred from the ICU to the HCU on the 10th day of treatment.

Respiratory failure in Guillain Barre Syndrome caused by respiratory muscle weakness might be worsened with aspiration pneumonia due to deficits of swallowing reflex. Nosocomial infection is an important complication in GBS, 25% patients experienced pneumonia and 30% urinary tract infection.

In this case, patient experienced respiratory failure with suspected pneumonia (cough, leukocytosis and infiltrates from chest imaging) after three days hospitalization (2 days treatment in RS T Purwakarta and 1 day in RSHS). Empiric antibiotics initially given were ceftazidime iv and levofloxacin. After four days treatment in the ICU, patient experienced fever and chest xray revealed in an increase in infiltrates thus antibiotics were replaced by meropenem while sputum was cultured.

On Day-8, sputum culture indicates *Pseudomonas aeruginosa* that is sensitive to gentamycin, amikacin, ciprofloxacin, meropenem and resistant to ceftazidime, cefazoline, tigecycline. Previously administered antibiotic was suitable with the results of culture and resistance, meropenem was continued as the patient's clinical progress was improving.

CONCLUSION

Guillain-Barre syndrome is a significant cause of acute disability and affects the patient's quality of life. Time of recovery is unpredictable and is usually slow. Some patients with GBS require assistance with mechanical ventilation as well as treatment in the ICU. The management of GBS patients can be given IVIG therapy or by plasmapheresis, both of which have the same effectiveness. Giving empiric antibiotics immediately after the patient has been diagnosed with suspect HAP will result in better outcome. Empiric antibiotics given immediately after the patient is suspected HAP will have better outcome.

RECOMMENDATION

From the current study, we recommend healthcare practitioners to perform either IVIG therapy or plasmapheresis for GBS patient. Some GBS patients with respiratory failure require mechanical ventilation and ICU. Empiric antibiotics are recommended to be given immediately if the patient is suspected with HAP.

REFERENCES

1. Mishra, A., Tiwari, K.K. & Gudi, S.K. (2017). Guillain-barre syndrome (GBS). An Orphan Disease. *World J Pharmaceutical*, 6(5), 393–400
2. Verboon, C., van Doorn, P. A., & Jacobs, B. C. (2017). Treatment dilemmas in Guillain-Barré syndrome. *Journal of Neurology, Neurosurgery & Psychiatry*, 88(4), 346-352.
3. Bhagat, H., Dash, H. H., Chauhan, R. S., Khanna, P., & Bithal, P. K. (2014). Intensive care management of Guillain-Barre syndrome: a retrospective outcome study and review of literature. *Journal of Neuroanaesthesiology and Critical Care*, 1(03), 188-197.
4. Kishore, C.K., Vijayabhaskar, J., Vardhan, R. V., Sainaresh, V.V., Siramnaveen, P., Sridhar, A.V.S.S.N., ... & Kumar, S. (2014). Management of FUillan-Barre syndrome with plasmapheresis or immunoglobulin: our experience from a tertiary care institute in South India. *Renal Failure*, 36(5), 732-736.
5. McGrogan, A., Madle, G. C., Seaman, H. E., & De Vries, C. S. (2009). The epidemiology of Guillain-Barré syndrome worldwide. *Neuroepidemiology*, 32(2), 150-163.
6. González, P., García, X., Guerra, A., Arango, J. C., Delgado, H., Uribe, C. S., ... & Hernández, O. (2016). Experience with Guillain-Barré syndrome in a neurological intensive care unit. *Neurología (English Edition)*, 31(6), 389-394.
7. Joshi, K., Patel, M., Gupta, R. & Bajaj, N. (2016) Guillain–barre syndrome: a case report. *Int J Med Sci Public Health*, 5,1295–1296.
8. Dharmayanti, A., & Astrawinata, D. (2017). Ventilator-Associated Pneumonia (VAP) in a Patient with Guillain-Barre Syndrome. *Acta Medica Indonesiana*, 49(2), 151-157.
9. Meena, A. K., Khadilkar, S. V., & Murthy, J. M. K. (2011). Treatment guidelines for Guillain–Barré syndrome. *Annals of Indian Academy of Neurology*, 14(Suppl1), S73.
10. Van Doorn, P. A., Ruts, L., & Jacobs, B. C. (2008). Clinical features, pathogenesis, and treatment of Guillain-Barré syndrome. *The Lancet Neurology*, 7(10), 939-950.
11. Fridey, J.L. (2017) Therapeutic apheresis (Plasma exchange or cytapheresis): indcation and technology. *JA Silvergleid eds*.